Case Report showing Pediatric Healthcare Disparities in Border Medicine during Covid-19 pandemic

Ana H. Almeda, MD[1], Daniel Anh, MD[2], Ambrosio Hernandez, MD[3], Dustin J. Paul, DO[4]

1.The University of Texas Rio Grande Valley at Doctors Hospital at Renaissance Transitional Year Residency Program.
2. The University of Texas Rio Grande Valley at Doctors Hospital at Renaissance General Surgery Residency Program
3. Driscoll Children's Hospital
4. The University of Texas Rio Grande Valley Neurology Department

Introduction

In February 2021, more than 500,000 people have lost their lives due to the novel coronavirus (COVID-19)[1]. Children have been considered relatively spared compared to adults with lower hospitalization and mortality rates[2]. However, children are indeed experiencing serious disease in the form of Multisystem Inflammatory in children (MIS-C) and border health disparities may confound their illness

Case Presentation

14-year-old Hispanic male admitted to Rio Grande Valley Pediatric Intensive Care Unit. The patient is morbidly obese male without any known significant past medical history. He presented with new onset seizures associated with COVID-19 infection. The patient was initially evaluated at an outside emergency room with seizure activity preceded by one-week history of fever and exposure to his mother who was COVID-19 positive. Emergency Medical Services (EMS) was called to the home. His blood pressure was 169/101 mmHg in the emergency room. His preliminary laboratories were significant for elevated BUN and Creatinine, 102mg/dL and 26 mg/dL, respectively and consistent with severe kidney injury. He was confirmed to be SARS-CoV-2 positive by PCR. A computerized tomography (CT) of the head was normal. He was transferred to our pediatric intensive care unit for dialysis management.

Upon review of systems, his family noted decrease oral intake, vomiting, diarrhea, weight loss, and decreased urine output with urinary changes over three months. His mother recalled the patient having episodes of high blood pressure on well-checks, but was never formally diagnosed with hypertension or received a complete work up to evaluate the etiology. He was tested for SARS CoV-2 six days prior to his presentation by his PCP but only received positive results two days prior to admission.

During his hospitalization, he received packed red blood cell transfusion prior to laparoscopic peritoneal dialysis catheter placement and hemodialysis catheter placement for emergent dialysis. Over the following two days, his hypertension became refractory to the initial treatment. He required numerous antihypertensives to address his hypertensive emergency.
He was treated with a transfusion of convalescent plasma and received dexamethasone 6mg IV to address COVID infection. An Intravenous Immunoglobulin (IVIG) was attempted but stopped due to allergic reaction to the infusion. He required daily hemodialysis until his metabolic acidosis corrected. He was transitioned to peritoneal dialysis. His neurologic status improved after day ten of illness, typically associated with peak of COVID symptoms and discharged home.

Clinic Findings-Imaging

A renal ultrasound revealed bilateral hypotrophic kidneys measuring dimensions of 7cm x 4cm x 4 cm and 6.5cm x 3cm x 3 cm with cortical thinning and increased echogenicity consistent with undiagnosed chronic medical renal disease. ECHO cardiogram showed mild to moderate concentric left ventricular hypertrophy. MRI of the brain revealed high signal in diffuse weighted images (DWI) sequence and low signal in apparent diffusion coefficient (ADC) map in the subcortical white matter of both parietal lobes most consistent with restricted diffusion on the bilateral subcortical white matter of the parietal lobes. Posterior reversible encephalopathy syndrome was excluded due to lack of high T2/FLAIR signal seen in vasogenic edema. Electroencephalogram (EEG) showed abnormal activity consistent with mild to moderate encephalopathy.

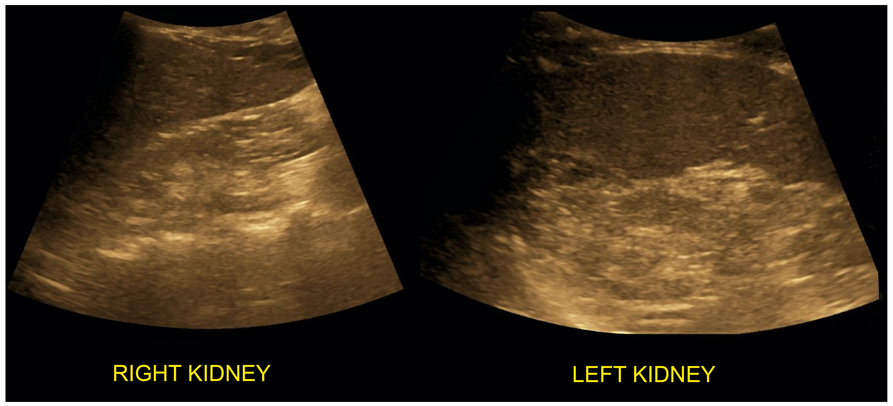

Image 1. Renal Ultrasound right and Left showing hypotrophy of kidneys bilaterally

7.8 / 6.9 / 135 / 24.7	133 | 101 | 102 / 139 4.5 | 9 | 26.3	PT 11.8 PTT 44.6 INR 1.1	SARS-CoV-2 PCR +

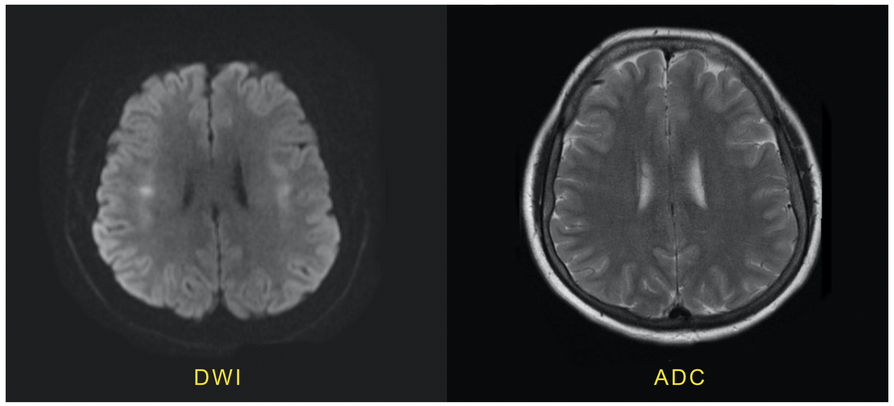

Image 2. MRI Brain Diffused Weighted Image and Apparent Deficient Coefficient images

Discussion

This patient was diagnosed with Multisystem Inflammatory Syndrome in Children (MIS-C) seen with COVID-19 infection in pediatric population. His COVID associated illness was confounded by factors that may be.
unique to border health medicine. This child lived in rural border town without dedicated pediatric subspecialists. He travelled over 50 miles to get to the emergency room in which he received initial medical attention. He required care by a pediatric nephrologist to initiate the lifesaving dialysis which prompted a transfer to another facility in order to receive care by pediatric subspecialists not available at the initial facility further delaying his medical care.

While the patient was not diagnosed with any medical problems prior to his presentation, the studies performed showed likely long-standing anatomical and physiological changes seen in chronic medical disease The renal ultrasound findings of hypotrophic kidneys and renal cortex thinning are consistent with a chronic renal disease that was undiagnosed in this patient. He was likely born with underdeveloped kidneys, but was never diagnosed or treated. His elevated blood pressure that only marginally responded to initial antihypertensives was concerning for severe long-standing undiagnosed hypertension. The ECHO cardiogram showed changes in the left ventricle consistent with chronic changes of hypertension. While the mother admitted to previous episodes of elevated blood pressure, he was not formally diagnosed or received a diagnostic work up to address his hypertension. Access to health care in border cities can be challenging compared to urban communities. This patient lived in a small remote border city removed from even other border cities with access to specialized pediatric medical services.

Conclusions

While generally speaking, children are less severely affected by COVID-19 compared to adults, border community children may be at unique risk for severe disease due to health care disparities seen in the border. Lack of accessibility to health care and pediatric specialists may hinder these patients access to routine, preventive health care, and acute critical care.

References

1. COVID Data Tracker. Centers for Disease Control and Prevention Accessed February 27, 2021. https://covid.cdc.gov/covid-data-tracker/#datatracker-home
2. CDC COVID-19 Response Team. Coronavirus disease 2019 in children – United States, February 12- April 2, 2020. MMWR Morb Mortal Wkly Rep. 2020;69(14):422-426.

Compounded trauma among recently immigrated families fleeing violence

Frances R. Morales, Andy Torres, Maria Sevilla-Matos, & Alfonso Mercado
The University of Texas Rio Grande Valley

Recent shifts in migration patterns

The current pattern of Hispanic/Latinx immigration to the U.S. is remarkably different from previously observed patterns.

Over the last decade, a large increase in the number of children and families from Central America migrating to the U.S. has been documented.

This wave of asylum-seekers mainly originates from El Salvador, Guatemala, and Honduras (countries collectively known as the "Northern Triangle").

A rising proportion of those arriving at the Southern border are requesting asylum, whether at official ports of entry or after entering the U.S. "without inspection" between U.S. ports of entry (O'Connor et al., 2019).

Source:https://www.kqed.org/lowdown/31036/why-so-many-people-in-the-northern-triangle-are-seeking-u-s-asylum

Stifling poverty and rising levels of crime and violence contribute to their desire to flee their country.

Central American families are making the difficult decision to leave their homes in search of safety and a better life despite the risk of being kidnapped, trafficked, raped or even killed along their way (UNICEF USA, 2019).

This group of immigrants is severely affected by the excessive violence in their countries and exposure to other forms of trauma (Mercado et al., 2019).

This population faces immense hardship not only prior to leaving their home country, but also during and after their migratory journey upon arrival to the U.S. border.

The present study

Source: https://www.foxnews.com/world/on-board-the-beast-immigrants-make-perilous-journey-to-u-s

Exposure to violence and other traumatic events are both risk factors for PTSD. Thus, trauma-related distress and symptoms are likely on the rise among recent waves of Hispanic/Latinx immigrant families.

This study measured trauma exposure and posttraumatic stress symptoms in a sample of recently immigrated families from Guatemala, Honduras, El Salvador, and Mexico.

Participants completed a previously validated Spanish translation of the Trauma History Questionnaire (Heilemann et al., 2005) to measure exposure to traumatic events.

This is a 24-item checklist that asks respondents whether they have experienced 24 possibly traumatic events.

Participants also completed the 22-item Spanish version of the Impact of Events Scale (Escala Revisada de Impacto del Estresor) to assess posttraumatic stress symptoms (Weiss & Marmar, 1997).

Analyses for this study included data from 97 participants, 43 males and 54 females.

Participants' ages ranged from 20 to 57 years of age (M = 34.44, SD = 7.53).

Analyses revealed that almost without exception the participants experienced some type of traumatic event.

The majority of participants (70%) endorsed experiencing crime related trauma and almost half (46%) reported experiencing physical or sexual trauma.

Findings also revealed high rates of PTSS among participants.

Compounded trauma

Migrants arriving at the U.S. border may present or are at risk of developing significant mental health symptoms in response to violence and trauma exposure.

But, a great deal more alarming, is the fact that the traumatic experiences do not end at the border for these vulnerable individuals as they attempt to request asylum in the U.S.

Their ordeal continues as they wait either in holding facilities for their processing to be completed before they can be released or transferred to another federal agency or are sent back to Mexico to wait in tent open-air encampments.

The Migrant Protection Protocols (MPP) program, colloquially known as "Remain in Mexico," forces individuals and families to wait for their court hearings in unsafe environments in Mexico for many months where they are at great risk of assault, mistreatment, and trauma.

Psychologists and other mental health providers can support the migrant population by taking into account their unique circumstances, providing clinical services that address their distinct needs, and advocating for policies that increases their access to mental health services.

This paper aims to increase awareness of the multiple challenges and stressors faced by immigrant families and to enhance our understanding about how these can compound the trauma already experienced by immigrants arriving to our country.

References Upon Request